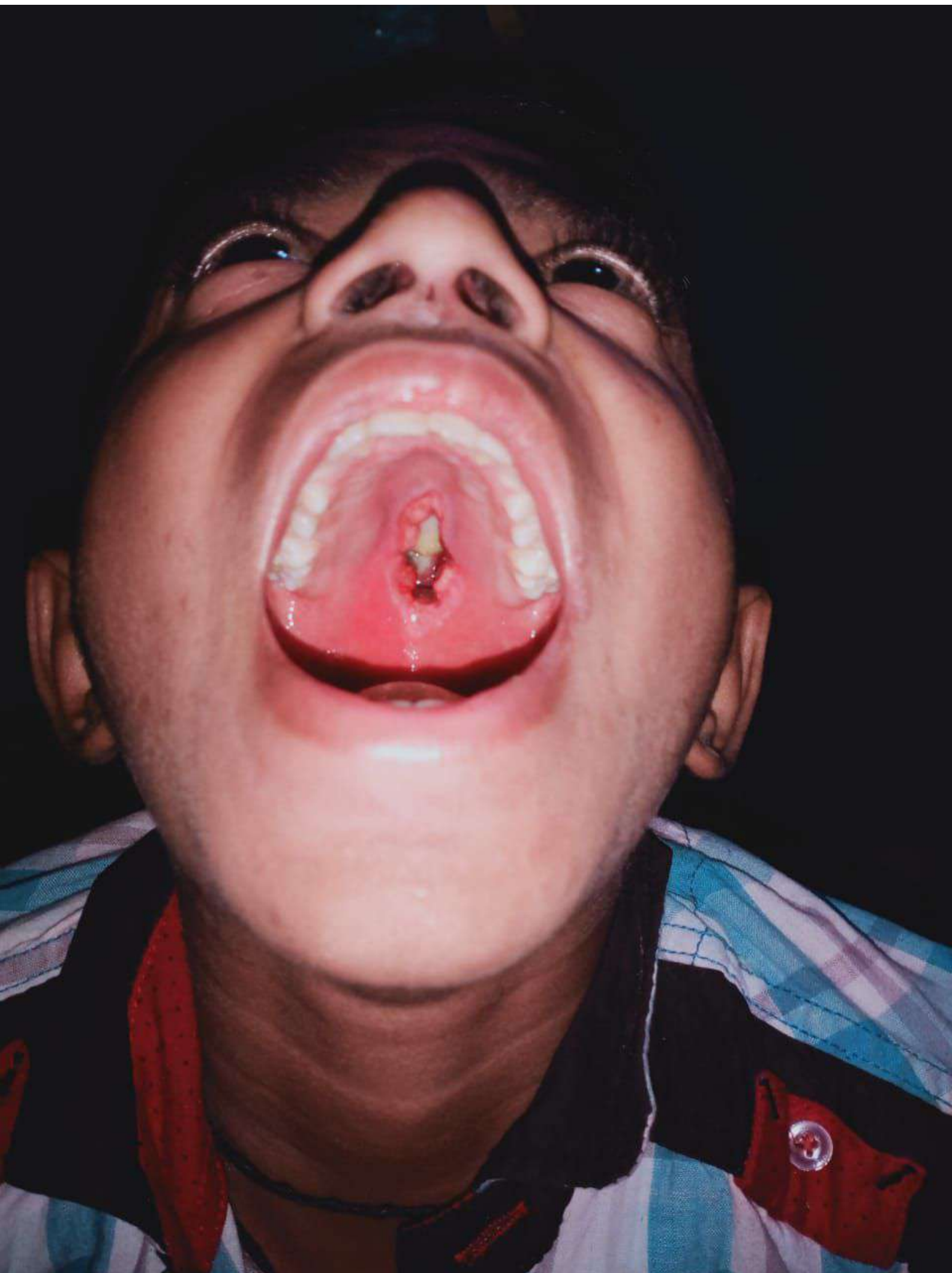





डा. बी. आर. अम्बेडकर संस्थान रोटरी कैंसर अस्पताल
Dr. B.R. Ambedkar Institute Rotary Cancer Hospital

I.M.S. HOSPITAL
Patient Department
PROHIBITED IN HOSPITAL PREMISES

OPR-6

ID: 105298178



General

एकतः IRCH No. 253747

विधा: नाम
Name: NABIRAJA

SD-ELARCON

Phone No. 011-2337645

Sex/Age: M/45

रोगीको पंजीकृत सं/ O.P.D. Regn. No.

| लिंग Sex | उम्र Age | जन्म तिथि/Date of Birth |
|-------------|-------------|-------------------------|
| | | |

निदान/Diagnosis

T-NHL-N₂

दिनांक/Date

उपचार/Treatment

1/4/2022

AA #1

1. Inj. DEXONA

12mg in 100ml NS

d1-3

2nd dose
3/4/22

2. Inj. VCA

1.2mg

IVP-d1

3. Inj. IFOSFAMIDE

in 100ml NS

d1-3 → 1g

9013677877

4. Inj. Mesna

400mg IVP

- AA d 2 & 3

d1-3

5. Inj. AA-C

in 100ml NS B12

d2 → 120mg

d3 → 120mg

120

~~120~~mg

~~120~~mg

अंगदान-जीवन का बहुमूल्य उपहार/ORGAN DONATION - A GIFT OF LIFE

O.R.B.O., AIIMS, 26588360, 26593444, www.orbo.org Helpline - 1060 (24 hrs service)

बाहर से आने वाले रोगियों के लिए धर्मशाला की सुविधा उपलब्ध है/Dharamshala facility is available for outstation patients

6. Inj VP-16 in 10 57. Δ

d2 \rightarrow 80mg

d3 \rightarrow 80mg

7. Inj. Zofen 4mg ivp d1-3

I Zofen 4mg \circ \longleftarrow \longrightarrow \circ d1-5

8000 units IN

9. Inj. Bionase

- d1, d3, d5, d7

10. Inj. G-CSF 150mcg ^{slc} ~~off~~ 6 day ^{direct} _{note}
~~d~~ from d# 5

11. CSF cytopenia

+ IT Mtx 12mg
TIT \leftarrow IT AAPE 20mg
IT hydrocort 15mg

at 8:30am

9/4/2021

12. For mouth Cascon 12/4

Sanjour



Department Of Pathology
All India Institute Of Medical Sciences
Delhi

Tel: +91-11-26588500/26588700 Fax: +91-11-26588500/26588700

| | | | |
|------------------|-----------------------|---------------------|-------------------|
| Patient Name | Nabi Raja | Acc No | 217231 |
| F/H Name | Haroon | Hosp Reg No | 253747 |
| Age/Sex | 11 Y/Male | UHID No | --- |
| Clinic/Dept/Unit | Dr. B R A IRCH/Unit 1 | Consultant Incharge | Dr Sameer Bakhshi |
| Reg Date | 09-03-2021 | Reporting Date | 17-03-2021 |

Histopathology Report

Report Findings:

Adequate bone marrow biopsy shows cellularity of approximately 80-90%. Trilineage hematopoiesis is noted. There is no evidence of lymphoma infiltration in the sections examined.

Kindly correlate with corresponding imprint smear findings.

Reporting Incharge: Dr. Prashant Ramteke

Reporting SR: Dr. Rimlee Dutta

Verify By: Dr. Charli



Department Of Pathology
All India Institute Of Medical Sciences
Delhi

Tel: +91-11-26588500/26588700 Fax: +91-11-26588500/26588700

Patient Name: **Nabi Raja**
Filt Name: Haroon
Age/Sex: 1 Y/Male
Clinic/Dept/Unit: ENT/Inft.1
Reg Date: 13-02-2021

Acc No: 214337
Hosp Reg No: 105298178
UHID No: ---
Consultant Incharge: Dr. Chirom Amit Sr
Reporting Date: 01-03-2021

Histopathology Report

Report Findings:

Biopsy from "oral cavity fistula site" comprises of multiple soft tissues measuring together 0.4x0.2x0.1cm.

Sections examined show multiple mucosal fragments, with ulceration of the overlying mucosa. Submucosa shows infiltration by intermediate to large sized atypical lymphoid cells with marked nuclear atypia. Few of the cells show oval to elongated nuclei. The cells are immunopositive for LCA granzyme (focal) while they are negative for CD3, CD20, CD56, CD68, MPO, desmin and myogenin. Morphological features are in favour of an aggressive hematolymphoid malignancy. Further immunohistochemistry is being done and a supplementary report will follow.

Reporting Incharge: Dr. Saumyaranjan Mallick

Reporting SR: Dr. Rimlee Dutta
Verify By: Dr. Rimlee



Department Of Pathology
All India Institute Of Medical Sciences
Delhi

Tel: +91-11-26588500/26588700, Fax: +91-11-26588500/26588700

| | |
|-------------------------------------|---|
| Patient Name: N. Raja | Acc No: 21291 |
| F/H Name: | Hosp. Reg. No: 105298178 |
| Age/Sex: 11 Y/Male | UHID No: --- |
| Clinic/Dept/Unit: ENT/Unit 1 | Consultant Incharge: Dr. Alok Thakar |
| Reg Date: 05-01-2021 | Reporting Date: 12-01-2021 |

Histopathology Report

Report Findings:

Biopsy from edge of palatal fistula shows fragments of squamous mucosa with ulceration, inflammatory granulation tissue formation and overlying acute inflammatory exudate.

There is pseudoepitheliomatous hyperplasia of squamous epithelium, and squamous metaplasia of ducts of underlying salivary gland lobules; however necrosis of lobules is not identified. The squamous epithelium shows reactive atypia at places. There is no definite evidence of malignancy in this biopsy. Kindly discuss with the undersigned if there is clinical suspicion of the same.

Reporting Incharge: **Dr. Aanchal Kakkar**

Reporting SR: **Dr. Nitesh R. wat**

Verify By: **Dr. Sachita Pandey**



TB LABORATORY (ROOM NO. 2056)
टीबी प्रयोगशाला (कमरा सं। 2056)
DEPARTMENT OF MICROBIOLOGY
A.I.I.M.S., New Delhi-110029
ए. आर. आर. नं., नई दिल्ली-110029



| | | | |
|-----------------------|-----------------------------|-------------------------|---|
| UHID | : 105298175 | Reg Date : | 24/12/2020 06:04 AM |
| Patient Name | : Master. NABI RAJA | | |
| Sex | : Male | Age : | 11 years 11 days |
| Department : | DEPT. OF EMERGENCY MEDICINE | Unit Name : | Unit-I |
| Unit Incharge : | Dr. Praveen Aggarwal | Sample Collection Date: | 04/01/2021 12:56 PM |
| Lab Name: | Microbiology | Lab Sub Centre: | TB Lab Ziehl Neelsen Staining for Acid Fast Bacilli (Microbiology room no 2056) |
| Sample Received Date: | 04/01/2021 12:59 PM | Report Generated Date: | 05/01/2021 11:51 AM |
| Dept / RCH No: | 20210090001254 | Recommended By: | Dr. Praveen Aggarwal |
| Lab Reference No. | 34 | | |

Sample Details : TB-ZN-040121016 (Tissue Biopsy)

TISSUE BIOPSY FOR ZN STAINING (TAT:24 HRS)

Result of investigation:

Result: **Negative for Acid fast bacilli**

Sample Remarks : According to RNTCP

- 1 1-9AFB /100field Scanty or exact no. of AFB seen
- 2 10-99AFB/minimum of 100 fields 1 +
- 3 1-10/minimum of 50 fields 2 +
- 4 1-10/minimum of 20 fields 3+

Authorized Signatory

Abdo ~~CECT~~

→ CECT Wood Mack

→ To review & Br report of CECT in ERIT OPD

Room No 4110 Dr. Gaman ~~ERIT~~ Tues/Friday Total appointment

→ A can take tentative appointment ~~form~~ for Matoulo clinic

Gaman
JREMI

5/3/21 C/K

~~HPE~~

HPE: atypical lymphoid cell - for CD3, HAM, gran zone
- for CD-8, Td B, Langerhans, CD1c s/o NK cell
lymphoma (Masa type)

PHYSICAL EXAMINATION



| Temp. | Pulse | Resp. | B.P. | Weight |
|-------|-------|-------|------|--------|
|-------|-------|-------|------|--------|

4/1/21
12:10 PM

e ECG & LA Taken in EMT not

- A focused, ~~see~~ LA infiltrated.
- multiple punch ECG taken → not for HPE & AFB
- Hemostasis achieved = Bipolar cautery.

Notes - Collect HPE after today (1085)

- Betadine (1:200) gargles BID
- Skan feeds
- Pub augmentin @ 325mg TDS x week
- Tel Pantop 40mg ODBB x week
- Pub PCM 300mg TDS x 3 days
- Rlu's Report

[Signature]
J.R. ENI

अखिल भारतीय आयुर्विज्ञान संस्थान, नई दिल्ली-110029
ALL INDIA INSTITUTE OF MEDICAL SCIENCES, NEW DELHI-110029

नाम Name: Not
उम्र Age: 4/12
सर्विस Service: _____
दिनांक Date: _____
यू एच आई डी नं. UHID No.: 1-5298172
प्रोफेसर इंचार्ज Professor I/C: _____
Notes written by: _____

CLINICAL NOTES

C/S/B Ear Rashes on col


21/12/22

40 O/C nasal abs x 1 M
nasal v/c
palatal fistula 15 days

Hx. fwi ⊕

not able to orally eat

Hx. sagittal ⊕





ALL INDIA INSTITUTE OF MEDICAL SCIENCES (AIIMS)
New Delhi

| | | | |
|---------------|-------------------|----------------|----------------------|
| UHD: | 105298178 | Reg Date: | 24/12/2020 06:04 AM |
| Patient Name: | Master. NABI RAJA | Age: | 11 years |
| Sex: | Male | Department: | Paediatrics |
| Unit Name: | Unit-1 | Unit Incharge: | Dr. Praveen Aggarwal |

Sample Details: MPS-241220017 (Pus) Collection Date: 24/12/2020 09:16 AM

Report Generated on: 30/12/2020 09:23 AM

Culture Report

Result of investigation:

Culture Result: More than 3 types of colonies predominantly GNB

Sample Details: MY-DC-241220020 (Pus) Collection Date: 24/12/2020 09:17 AM

Culture

Result of Investigation:

| | | | | |
|---------|------------|--------------------------------|--------|-----------------|
| Gender: | Age Range: | Biological Reference Interval: | Other: | Special Remark: |
|---------|------------|--------------------------------|--------|-----------------|

Result: Culture negative for fungi

Direct KOH

Result of Investigation:

| | | | | |
|---------|------------|--------------------------------|--------|-----------------|
| Gender: | Age Range: | Biological Reference Interval: | Other: | Special Remark: |
|---------|------------|--------------------------------|--------|-----------------|

Result: Sample negative for fungal elements.

Grams stain

Result of Investigation:

| | | | | |
|---------|------------|--------------------------------|--------|-----------------|
| Gender: | Age Range: | Biological Reference Interval: | Other: | Special Remark: |
|---------|------------|--------------------------------|--------|-----------------|

Result: Sample negative for fungi

Authorized Signatory

Patient's Name

BIRTH

4 Wks

10 Wks

14 Wks

6 Months

1 Year

1 1/2 Yrs

2 Yrs

3 Yrs

4-6 Yrs

8 Yrs

10-12 Yrs

15 Yrs+

सलाह

EMSC BLOOD TESTS
@ LB/M/L
URGENT

HRCT CHEST

NOT A CASE OF COVID
-19

REP
15.12.20

Dr. PRAKASH C. GUPTA
M.B.B.S. M.D. (Peds)
Senior Consultant
Pediatrics
S.P.T. Children's Hospital, Delhi

DOB RHE FD 1/6 - 00
①

REP
12.12.20

- ~~anti rubein titer~~
- sweat chloride test
- fecal fat estimation

- bronchogram • Endoscopy
- bronchoscopy

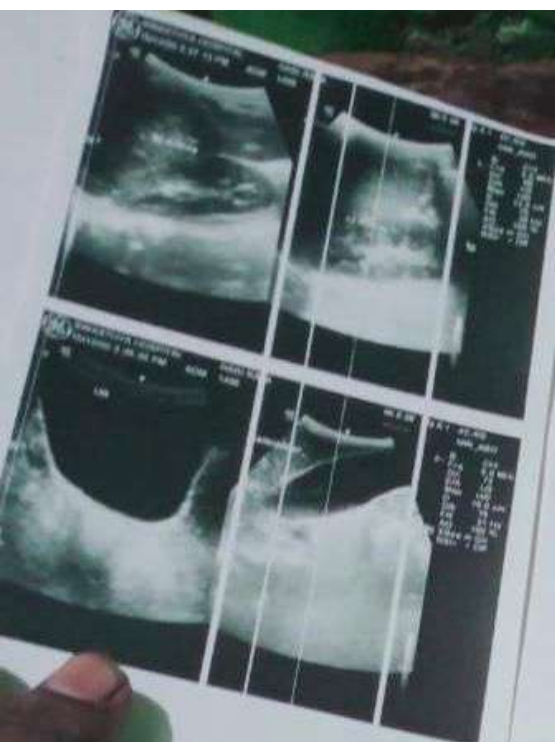
→ max Hsp
patrangam

STAIN GUM
PAINT

+ NOCTOGEL GEL

REP
17.12.20

VISIT



SWASTHYA
HOSPITAL

D-2/11, KRISHNA NAGAR
DELHI-110051
PH. 2200-3111, 2200-3635

NAME: Nishi Bora

AGE: 44yr

SEX: M/F

Referred by Dr. C. Gupta

Date: 15/11/2020

ULTRASOUND REPORT

LIVER

Normal AP size 12cm
LIVER IS NORMAL IN SIZE & ECHOTEXTURE. IHR ARE NORMAL. NO SOL SEEN IN THE LIVER

GALLBLADDER

IS ADEQUATELY DISTENDED AND SHOWS NORMAL THICKNESS.
NO ECHOGENIC SHADOW IS SEEN IN GALL BLADDER LUMEN.
COMMON DUCT AND PORTAL VEIN ARE NORMAL IN CALIBRE.

PANCREAS/KIDNEY

PANCREAS IS NORMAL IN SIZE AND ECHOTEXTURE. NO EVIDENCE OF PANCREATIC DUCT DILATION OR CALCIFICATION SEEN.

KIDNEYS:

BOTH THE KIDNEY ARE NORMAL IN SIZE, SHAPE AND ECHOTEXTURE. RENAL SINUS ECHOES ARE NORMAL ON BOTH SIDES. CORTICOMEDULLARY JUNCTION IS WELL DIFFERENTIATED. CONTROL THICKNESS IS NORMAL. PERINEPHRIC SPACE IS NORMAL.

RIGHT KIDNEY MEASURE

MM 6 X MM

LEFT KIDNEY MEASURE

MM 6 X MM

RETROPERITONEUM IS NORMAL

SPLEEN IS NORMAL IN SIZE AND ECHOTEXTURE.

NO FREE FLUID IS SEEN

URINARY BLADDER IS NORMAL IN SIZE, SHAPE AND WALL THICKNESS. NO EVIDENCE OF CALCULUS OR MASS LESION IS SEEN.

PROSTATE IS NORMAL IN APPEARANCE AND DIMENSIONS IT MEASURES

X X MM

APPROX PROSTATIC WEIGHT IS _____ GMS

POST VOIDING RESIDUAL IS INSIGNIFICANT

UTERUS _____ POSITIONS

SIZE: AP _____ x TR _____ x LG _____

ENDOMETRIUM _____

OTHERS _____

ADENAX RI Ovary

LI Ovary

*Bevel: @ Lumen @ Wall thickness
No mesenteric LN seen*

sup. Hepatomegaly

NCU
Consultant Radiologist

This is a professional opinion, not the Diagnosis. For this please correlate clinically.



6-991157645-78-99

181

नाम NAME: MASTER NABI RAJA

आयु AGE: 11 years

लिंग/SEX: M

S/O: HANSHU

उप-पता ADDRESS

मकान संख्या H NO: 1505 NR JAMA MASHI
गांव/प्रखंड CHY/BLOCK: G B NGR
राज्य STATE: UTTAR PRADESH
मोबाइल MOBILE NO: 991157645

पत्नी: मुहल्ला STREET/MOH: SEC 8 NORTH
पिन PIN: 201001

दूरभाष नं. PHONE NO:

स्थान Location:

Paediatric Emergency

Criticality: Red / Yellow / Green

द्वारा BROUGHT BY: Relative BROTHER

Triage: Responsive/Unresponsive

HR 128/min

BP

mmHg RR 20/min

SpO2 96%

Shifted to Paeds/ Main/ New Emergency

Presenting Complaints

h/o 1st sibling death at 13 yrs ? reason

h/o fever 15 days (subacute > 1 week)
cough persisting from 5 yrs
h/o recurrent upper respiratory infections childhood

TB w/o negative (from history)

Primary Assessment (ABCDE): Assessment Pentagon

h/o ulcer on palate: 15 days ? fistula

Airway

no I/H of TB

Open & stable: Yes/No
If No

Breathing: RR 20/min

Efforts: Normal/Poor/increased

Auscultation:

Air entry:

Normal/poor/Differential

Added sounds:

None/Stridor/Wheeze/Crackles

SpO2 on Room air

⊖ infra mammary

LDNA ↑↑↑

Circulation

HR 128/min

CFT 2 sec

BP mmHg

Peripheral pulse: Poor/Good

Central pulse: Poor/Good

Skin temp: Warm/cool

Others

? fistula palati

clubbing (+)
gr II

Disability

GCS 15/15

Pupil size 2mm/min

Pupillary Reactions: GRV

Motor activity:

Normal & Symmetrical/Asymmetrical

Posturing/Flaccidity/Seizure

Blood Sugar mg/dl

Exposure:

Temp: ~~afebrile~~ warm

Colour: Normal/pallor/cyanosis/mottled

Any other skin lesions

Diagnosis

? Cystic fibrosis ? PCP
? nasal polyps

Wt: - 22

ENT R/V
ulms call



Growth Chart


Dr. Nakul Gupta
M.B.B.S., DCH, DEM, PGDS
SPECIALIST & NEONATOLOGIST
Formerly at - Shri Krishna Narain Dal Chikitsalya
(D.M.C. Reg. No. 08351)

Dr. Prakash C. Gupta
M.B.B.S., M.D. (PED)
CHILD SPECIALIST & NEONATOLOGIST
Formerly at - Kalawati Saran Children's Hospital
(D.M.C. Reg. No. 12258)

NOB/10/10



- 1200 28 50
- FTF
- anemia
- PALATAL GLEET
- BRONCHOP
- abdominal fullness



10.6/10.990/P 77 / 50 / 10.50

- CBC & HGT
- 12mm ANTONOW KUP UDRL
- X-RAY CHEST PAW @ PNEUM
- URINELK
- USG abdomen

- i. TAB NTPM P 1/2 TOS
- ii. SE RGTAD PLUS SMI
- iii. SE JETCOF SMI
- iv. TAB JAX (2000) 1/2 TOS

SE RITCZINU SMI 50
BENOGLE CEMO y adu 12.12

Swasthya Hospital

(Opp. Central Park), Krishan Nagar, Delhi-110051
Ph: 011-22003111, 011-22003635, 011-42263385
12 Noon to 6 PM.
Appointment Ph: 011-22003635 - 9 AM to 11 AM
Day at Swasthya Hospital (by appointment only)

Kashmiri Devi Children's Clinic

Kailash Nagar, Opp. S.S. School, Main Road, Delhi-31
Ph: 011-22074930, 011-22074930, 9910015381
7:00 PM to 9 PM
Appointment Ph: 9910015381 - 9 AM to 11 AM

All Vaccinations (BCG, DPT, Hepatitis, Measles, Flu, Pneumonia, Rota Virus, Chickenpox Etc.) are given

एमर्जेंसी के लिये 011-22003111 पर Doctor on Duty से सम्पर्क करें

सलाह : नियुक्तों के वर्तमान एवं भावी स्वास्थ्य के लिये टीकाकरण अवसर करावें।

भारत सरकार
Unique Identification Authority of India


नामांकन क्रम / Enrollment No.: 1028/44107/01491

To
नबी रज़ा
Nabi Raza
S/O: Md. Harun
1505 jj colony
sector-8
Gautam Buddha Nagar **
Noida
Gautam Buddha Nagar Gautam Buddha Nagar
Uttar Pradesh 201301
9911157645

167844608
01/09/2014



MLF-76446083FT



आपका आधार क्रमांक / Your Aadhaar No. :

6492 0074 5418

आधार - आम आदमी का अधिकार



भारत सरकार

Government of India



नबी रज़ा
Nabi Raza
माता : मो. हारून
Mother : Md. Harun
जन्म तिथि / DOB : 01/09/2009
पुरुष / Male



6492 0074 5418

आधार - आम आदमी का अधिकार



भारत सरकार

Government of India



अनीस

Anis

जन्म तिथि/DOB: 18/03/1991

पुरुष/ MALE



7811 3238 0732

VID : 9179 4901 7632 2121

मेरा **आधार**, मेरी पहचान



भारतीय विशिष्ट पहचान प्राधिकरण

Unique Identification Authority of India

पता:

C/O हारून, 1505, नजदीक जामा मस्जिद, सेक्टर-8,
नोएडा, गौतमबुद्ध नगर,
उत्तर प्रदेश - 201301

Address:

C/O Haroon, 1505, Near Jama Masjid,
Sector-8, Noida, Gautam Buddha Nagar,
Uttar Pradesh - 201301



QR Code with Photograph

7811 3238 0732

VID : 9179 4901 7632 2121



help@uidai.gov.in

www.uidai.gov.in